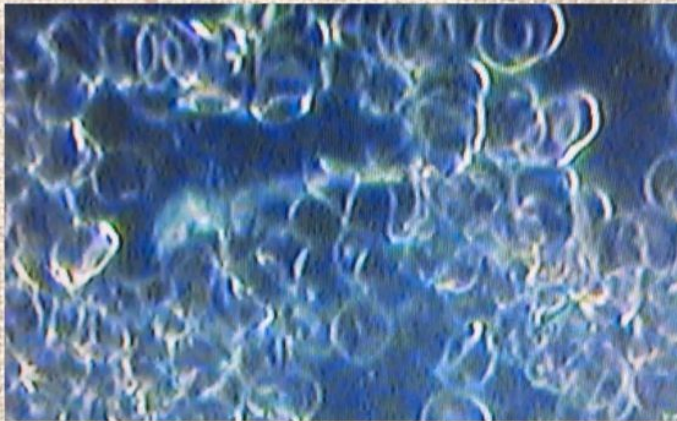
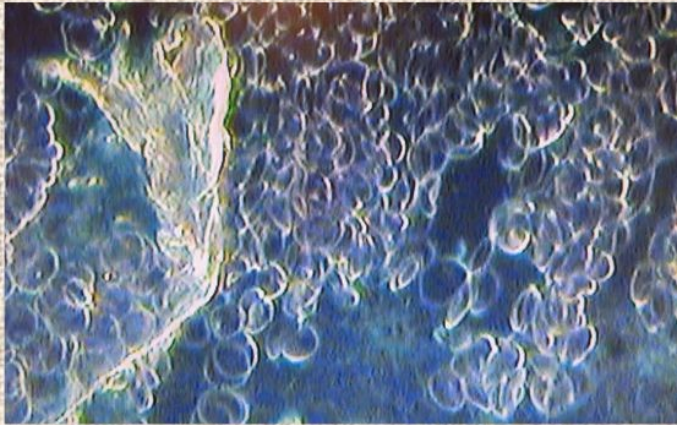
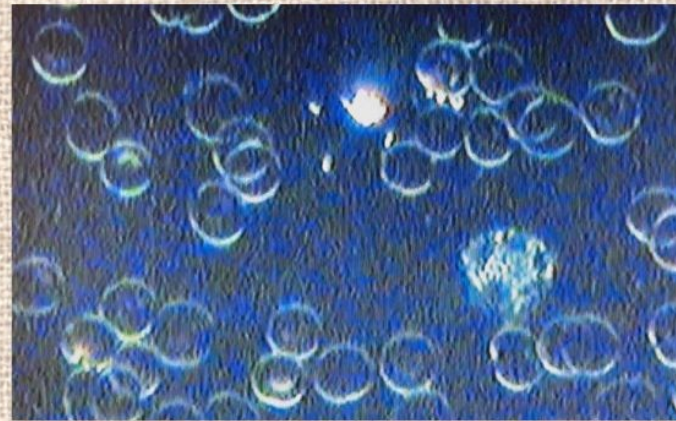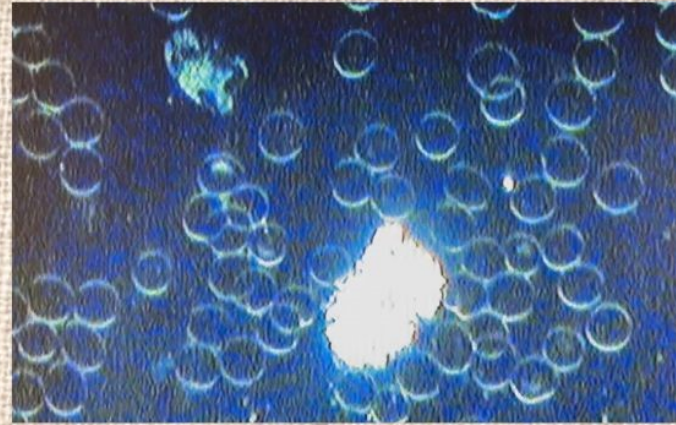


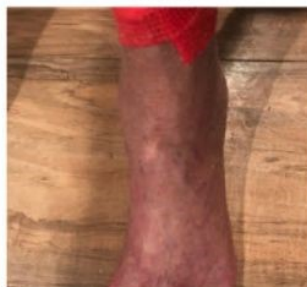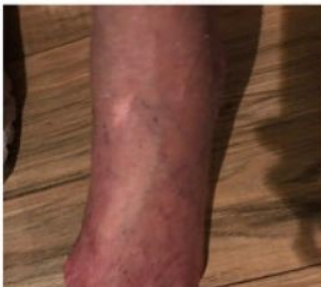Before Use of PEMF



After 8 Minutes of Use of PEMF



75 year old with wound on shin treated for months on Medicare.
8 minutes on a PEMF mat.
Before After



23 year old with scoliosis in pain.
Prognosis untreatable without surgery.
45 minutes with highly advanced microcurrent technology.

